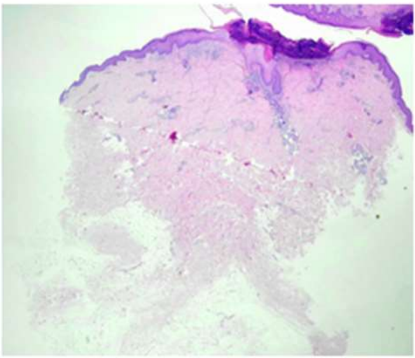
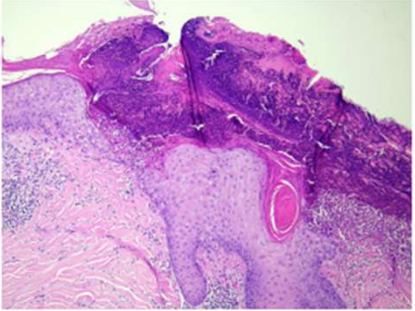
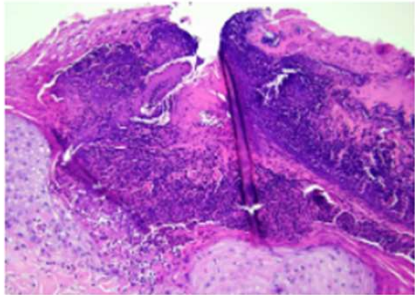


週	日期	時間	活動	Case of the week
一	11月13日			This is a 60-year-old male without underlying disease. He presented to our OPD with itchy erythematous to pigmented papules and nodules with central adherent scales over scalp and four limbs for two years.
二	11月14日	08:00-08:30	※ 臨床病例討論會 Mpox infection: cutaneous manifestations and management Posttherpetic pseudohernia R1 侯秉宸 (3F門診討論室) 【全科人員】 /VS 劉威廷 /VS 楊朝鈞	
三	11月15日	08:30-09:00	※ 出院病例討論會 R1 張藝瀚 (3F門診討論室) 【全科人員】	
		08:00-09:00	※ 住診教學 VS 朱家葆 (11B討論室) 【Clerks, PGYs, Rs】	
		13:00-14:00	※ 遺傳疾病討論會 / Prof. John McGrath & VS 許鈞凱 (3F門診討論室) 【全科人員】 1. Transcriptomic response of peripheral blood mononuclear cells to secukinumab in epidermolysis ichthyosis highlights the upregulation of interleukin-1 signaling R1 侯秉宸 2. A 15-year-old Female with Asymptomatic Pigmented Patches on the Right Chest for 3-4 Years R2 賴奕慈	
15:30-17:30	※ 外賓演講 (3F門診討論室/線上同步會議) 【全科人員】 Connective Tissue in Health, Cancer, Immunity, and Regeneration Prof. Gary J.Fisher Chemical genomics: compound screening for therapeutic drug development Dr. Yilei Cu			
四	11月16日	08:00-09:00	※ 年會預報 (3F門診討論室) 【全科人員】 1. Generalized pustular psoriasis caused by bupropion with rapid recurrence after self-rechallenge (1 min) PGY 鄭宇宸 2. Low-level TSC2 mosaicism in a Taiwanese female with tuberous sclerosis complex (TSC): a case report and literature review (12 mins) R1 張藝瀚 3. Painless hair transplants to improve wound healing for recessive dystrophic epidermolysis bullosa patients by iontophoretic local anesthesia (12 mins) R1 侯秉宸 4. Extracellular matrix components in androgenetic alopecia (12 mins) R2 賴奕慈 5. A simple pressure relief slippers to improve wound healing of diabetic foot ulcer (3 mins) R2 曾怡倫 6. Pazopanib combined low dose interferon alfa induced rapid regression of advanced classic Kaposi sarcoma (3 mins) R3 王瀚棠	  
五	11月17日	08:00-09:00	※ 住院醫師教學 VS 陳萱 (3F門診討論室) 【Rs】	
六	11月18日			
日	11月19日		※ 值班主治醫師查房 ※ Answers of the last week's case: xanthogranuloma	