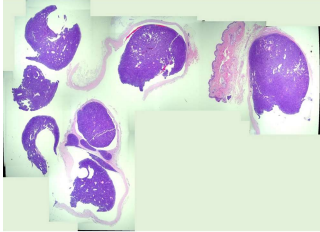
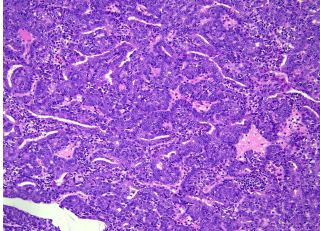
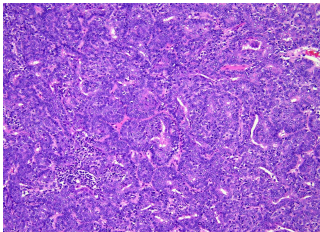


日期	時間	活動	Case of the week	
10/16 週一	08:00-09:00	※ 住院醫師年度考試 (3F門診) 【住院醫師】	40-year-old male with 2-cm asymptomatic nodule over left chest for years.	
10/17 週二	08:00-08:30	※ PGY Seminar PGY 鄭宇宸 / VS 劉威廷 (3F門診討論室) 【全科人員】 Analysis of Clinical Features and IL36RN Mutations in Generalized Pustular Psoriasis Patients of NCKUH		
	08:30-09:00	※ 出院病例討論會		
10/18 週三	08:00-09:00	※ 住診教學 / VS 杜威廷 (11B討論室) 【Clerks, PGYs, Rs】		
	13:00-15:00	※ 臨床病理討論會 (括弧內為討論重點) R2 曾怡倫 / VS 李玉雲 (3F門診討論室) 【全科人員】 1. Skin, scalp, biopsy: Compatible with cutaneous lupus erythematosus. (The clinicopathological review of discoid lupus erythematosus over scalp) / VS 楊朝鈞 2. Skin, cheek, right, biopsy: Perivascular and perifollicular dermatitis, compatible with Ofuji disea (The clinicopathological review of Ofuji disease) / R4 林 謙 3. Skin, forearm, right, shave biopsy: Compatible with lichen planus-like keratosis (The clinicopathological review of lichen planus-like keratosis) / VS 朱家葆 4. Skin, axilla, right; biopsy (The clinicopathological review of confluent and reticulated papillomatosis) / VS 王德華 5. Skin, index finger, right; excision: Squamous cell carcinoma in situ, subungual (at least). (The clinicopathological review of Subungual Bowen disease) / VS 李兆甯 6. Skin, forearm, left; biopsy: Compatible with hand-foot-mouth disease. (The clinico-pathological review of hand foot mouth disease and its differenital from erythema multiforme) / VS 何英右		
		15:00-16:00		※ 新知分享：結節性癢疹治療新趨勢 高雄長庚紀念醫院皮膚部 曾涵琪醫師(3F門診討論室)
		15:00-16:00		※ 臨床病例討論會 R1 張藝瀚 (3F門診討論室) 【全科人員】 1. Differential diagnoses for neonatal pustular dermatosis / VS 朱家葆 2. TCA application for vitiligo / VS 劉威廷
10/19 週四	08:00-09:00	※ 住院醫師讀書會: Fitzpatrick 9e Ch. 24-25 R3 葉芮苙 (3F門診討論室) 【住院醫師】		
10/20 週五	08:00-09:00	※ 住院醫師讀書會: Fitzpatrick 9e Ch. 24-25 R3 葉芮苙 (3F門診討論室) 【住院醫師】		
10/21 週六		※ 值班主治醫師查房	Answer for last week: Herpetic folliculitis	
10/22 週日				