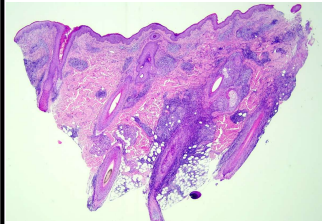
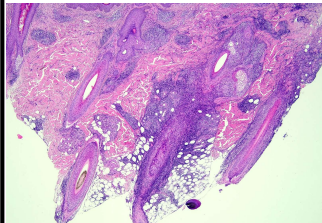
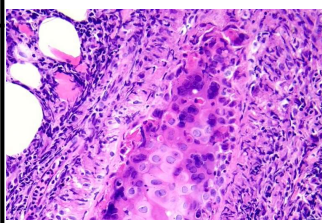

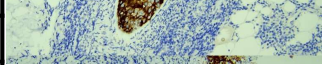


日期	時間	活動	Case of the week
10/9 週一			A 52-year-old male with painful infiltrative follicular plaques over the right temporal scalp and cheek for a week, not responding to oral antibiotics.
10/10 週二		※ 值班主治醫師查房 (雙十國定假日)	
10/11 週三	08:00-09:00	※ 住診教學 / VS 杜威廷 (11B討論室) 【Clerks, PGYs, Rs】	    
	13:00-15:00	※ 臨床病理討論會 (括弧內為討論重點) R2 曾怡倫 / VS 李玉雲 (3F門診討論室) 【全科人員】	
		1. Skin, forearm, right; biopsy: Spongiotic psoriasiform dermatitis with superficial fungal infection. (The clinicopathological review of erythema annulare centrifugum and annular skin lesions) / VS 朱家葆	
		2. Skin, flank, right; biopsy: Perforating collagenosis. (The clinicopathological review of reactive perforating collagenosis and acquired perforating disorders) / VS 李玉雲	
		3. Skin, scalp, biopsy: Suppurative granulation tissue, compatible with dissecting folliculitis. (The clinicopathological review of dissecting folliculitis) / VS 趙曉秋	
		4. Skin, chest, left, excision: Eccrine spiradenoma. (The clinicopathological review of Eccrine spiradenoma) / VS 許明隆	
	5. Skin, anterior shin near ankle, left; biopsy: Consistent with severe allergic reactions (contact/irritant dermatitis) with impetigo. (The clinicopathological review and differential of allergic and irritant contact dermatitis) / VS 許釗凱		
	6. Skin, lower lip; biopsy: Squamous cell carcinoma. (The clinicopathological review of Squamous cell carcinoma with perineural invasion) / VS 趙曉秋		
10/12 週四	08:00-09:00	※ 醫學期刊討論會 / VS 劉威廷 (3F門診討論室) 【全科人員】	
		1. Clinical Anatomy of the Chin Evaluated by 3-Dimensional Tomography and Cadaveric Dissection: Implications for Safety and Optimal Injection Techniques in Chinese. <i>Dermatol Surg.</i> 2023 Mar 1;49(3):237-241. R4 林謙	
		2. Perioperative imaging for high-stage cutaneous squamous cell carcinoma helps guide management in nearly a third of cases: A single-institution retrospective cohort. <i>J Am Acad Dermatol.</i> 2023 May;88(5):1209-1211. R4 林謙	
		3. Mpox: an updated review of dermatological manifestations in the current outbreak. <i>Br J Dermatol.</i> 2023 Aug 24;189(3):260-270. R3 葉芮彤	
		4. Skin toxicity of enfortumab vedotin: Proposal of a specific management algorithm. <i>J Eur Acad Dermatol Venereol.</i> 2023 Aug 22. R3 葉芮彤	
10/13 週五	08:00-09:00	※ 住院醫師讀書會: Fitzpatrick 9e Ch. 15 R4 黃信奮 (3F門診討論室) 【住院醫師】	
10/14 週六		※ 值班主治醫師查房	
10/15 週日			
			Answer for last week: Langerhan cell histiocytosis