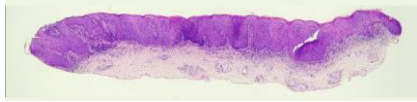

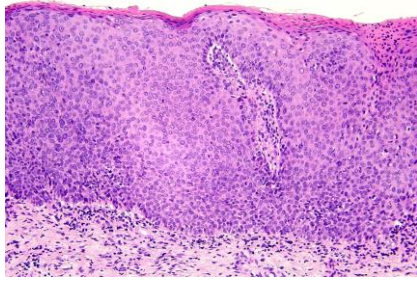
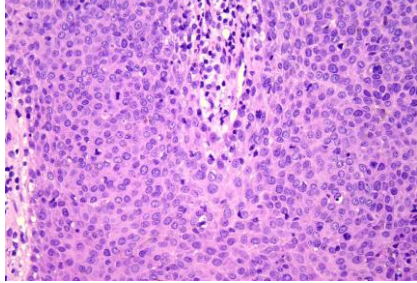


日期	時間	活動	Case of the week
8/28 週一			27 year-old male with several papillomatous papules on the prepuce for weeks
8/29 週二	08:00-08:30	※ 研究專題討論會 Unveiling the Pattern of CD123 in Lichen Planus-Lupus Erythematosus Overlap Syndrome R2 賴奕慈 / VS 劉威廷 (3F門診討論室) 【全科人員】	
	08:30-09:00	※ 出院病例討論會 R1 侯秉宸 (3F門診討論室) 【全科人員】	
8/30 週三	08:00-09:00	※ 住診教學 / VS 王德華 (11B討論室) 【Clerks, PGYs, Rs】	 HPV-   
	13:00-15:00	※ 臨床病理討論會 (括弧內為討論重點) R2 曾怡倫 / VS 李玉雲 (3F門診討論室) 【全科人員】	
		1. Skin, leg, left, biopsy: Consistent with erythema multiforme. (The clinicopathological review of erythema multiforme) / VS 許釗凱	
		2. Skin, thigh, right; biopsy with direct immunofluorescence: Consistent with urticarial vasculitis. (The clinicopathological review of urticarial vasculitis) / VS 劉威廷	
	3. Skin, forearm, left; biopsy: Compatible with lichen amyloidosis. (The clinicopathological review of lichen amyloidosis) / VS 朱家葆		
	4. Skin, posterior neck; biopsy: Lichen scleroedema. (The clinicopathological review of lichen scleroedema) / VS 李玉雲		
	5. Skin, palm, left, biopsy: Superficial perivascular infiltrate. (The clinicopathological review of eosinophil-associated-dermatoses) / R3 葉芮彤		
	6. Skin, parietal scalp, right; excision: Proliferating trichilemmal cyst. (The clinicopathological review of proliferating trichilemmal cyst) / VS 楊朝鈞		
	15:00-16:00	※ 產品介紹: 寶齡富錦公司 (3F門診討論室)	
8/31 週四	08:00-09:00	※ 住院醫師教學 VS 林宏謙 (3F門診討論室) 【住院醫師】	
9/1 週五	08:00-09:00	※ 住院醫師讀書會: Fitzpatrick 9e Ch. 12 R3 葉芮彤 (3F門診討論室) 【住院醫師】	
9/2 週六		※ 值班主治醫師查房	Answer for last week: Angiolymphoid hyperplasia with eosinophilia
9/3 週日			