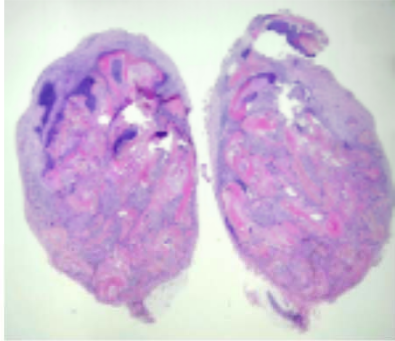
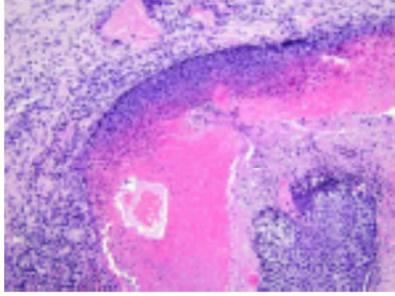


週	日期	時間	活動	Case of the week	
一	7月3日			This is a 13-year-old male without any underlying disease. She presented to OPD with one tender subcutaneous nodule on the right neck for 2-3 months.	
二	7月4日	08:00-08:30	※ 臨床病例討論會 Review of JAKi induced rash Management of giant congenital nevus R2 王瀚棠 (3F門診討論室) 【全科人員】 /VS 朱家葆 /VS 許釗凱		
		08:30-09:00	※ 出院病例討論會 R1 賴奕慈 (3F門診討論室) 【全科人員】		
三	7月5日	08:00-09:00	※ 住診教學 VS 廖怡貞 (11B討論室) 【Clerks, PGYs, Rs】		
		13:00-15:00	※ 臨床病理討論會 (括弧內為討論重點) R1 曾怡倫 /VS 李玉雲 (3F門診討論室) 【全科人員】 1. Skin, anterior chest, excision: Syringocystadenoma papilliferum. (The clinicopathological review of syringocystadenoma papilliferum) /VS 朱家葆 2. Skin, thigh, right; biopsy: Mild spongiotic psoriasiform dermatitis with a subcorneal pustule. (The clinicopathological differentiation of AGEP and pustular psoriasis) /VS 李兆甯 3. Skin, forearm, right; biopsy: Superficial and deep perivascular dermatitis, compatible with tumid lupus erythematosus. (The clinicopathological review of tumid lupus erythematosus with clusters of CD123-positive Plasmacytoid Dendritic Cells) /VS 廖怡貞 4. Skin, flank, left; biopsy: Compatible with mastocytosis. (The clinicopathological review of cutaneous mastocytosis) /VS 趙曉秋 5. Skin, left flank, biopsy: calcinosis cutis, possible dermatomyositis related. (The clinicopathological review of calcinosis in dermatomyositis) /VS 王德華 6. Skin, left planta area, biopsy: psoriasis. (The clinicopathological review of palmoplantar psoriasis and differential diagnosis of dyshidrotic eczema) /VS 杜威廷		
四	7月6日	08:00-08:30	※ 皮膚外科討論會 R1 曾怡倫 (3F門診討論室) 【全科人員】 Investigating the Anatomic Location of Soft Tissue Fillers in Noninflammatory Nodule Formation: An Ultrasound-Imaging-Based Analysis (Dermatol Surg. 2023 Jun 1;49(6):588-595.) /VS 何英右		
		08:30-09:00	※ 研究討論會 VS 何英右 (3F門診討論室) 【全科人員】 Reconstruction technique for skin cancer		
五	7月7日	08:00-09:00	※ 住院醫師讀書會: Fitzpatrick 9e Ch. 198 R1 賴奕慈 (3F門診討論室) 【Rs】		
六	7月8日		※ 值班主治醫師查房		
日	7月9日		※ Answers of the last week's case: pemphigus vulgaris		