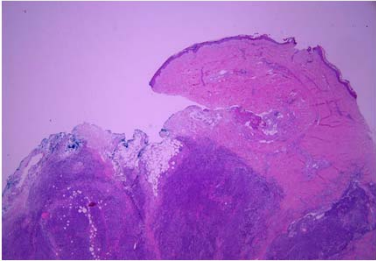
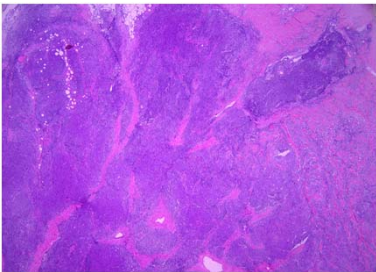
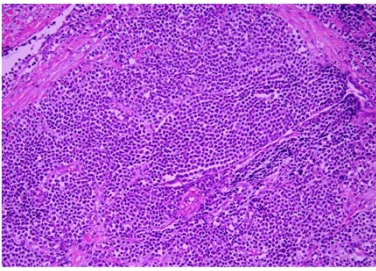
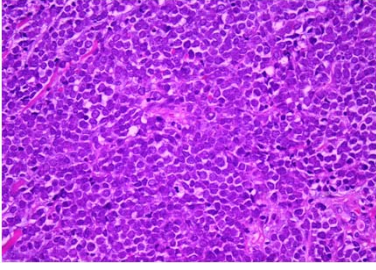


週	日期	時間	活動	Case of the week
一	5/29			This is a 60-year-old male with underlying disease of HTN,DM, dyslipidemia. He presented to OPD with a enlarging asymptomatic solitary brownish nodule on left calf for 4 months.
二	5/30	08:00-08:30	※ <b>PGY seminar</b> PGY1李孟羚 (3F門診討論室) 【全科人員】 Topical mTOR inhibitor use in Pachyonychia Congenita /VS 杜威廷	
		08:30-09:00	※ <b>PGY seminar</b> PGY1蘇資清 (3F門診討論室) 【全科人員】 Topical statin, the novel treatment of Porokeratosis /VS 何英右	
三	5/31	08:00-09:00	※ <b>住診教學</b> VS 許釗凱 (11B討論室) 【Clerks, PGYs, Rs】	   
		13:00-15:00	※ <b>臨床病理討論會</b> (括弧內為討論重點) R2 王瀚棠 /VS 李玉雲 (3F門診討論室) 【全科人員】 1. Skin, scalp; excision: Sarcomatoid tumor, favor sarcomatoid carcinoma. (Clinicopathological review sarcomatoid carcinoma and inflammatory myofibroblastic tumour) /VS 潘信誠 2. Skin, left neck, biopsy: Atypical lymphoid hyperplasia. (Clinicopathological review of atypical lymphoid hyperplasia) /VS 楊朝鈞 3. Skin, left index finger, biopsy: Interstitial granulomatous dermatitis. (Clinicopathological review of interstitial granulomatous dermatitis of digits) /VS 杜威廷 4. Skin, left postauricular region, excision: Compatible with epidermal keratinous cyst with rupture. (Clinicopathological review of branchial cleft cyst) /VS 何英右 5. Skin, forearm, left; biopsy: Superficial perivascular dermatitis with melanophages. (Clinicopathological review of ashly dermatosis) /VS 王德華 6. Skin, forearm, left; biopsy: neutrophilic dermatosis. (Clinicopathological review of neutrophilic dermatosis on postmastectomy lymphedema) /VS 王德華	
		08:00-08:30	※ <b>皮膚外科討論會</b> R2 葉芮苒 (3F門診討論室) 【全科人員】 Tertiary Revision of a Failed Nasal Reconstruction. (Dermatol Surg. 2023 May 1;49(5):503-505.) /vs 何英右	
		08:30-09:00	※ <b>期刊討論會</b> R1 賴奕慈 (3F門診討論室) 【全科人員】 EGFR Signaling Is Overactive in Pachyonychia Congenita: Effective Treatment with Oral Erlotinib. (J Invest Dermatol. 2023 Feb;143(2):294-304.e8.) /vs 杜威廷	
		08:00-09:00	※ <b>住院醫師讀書會</b> : Fitzpatrick 9e Ch. 191 R3 黃信奮 (3F門診討論室) 【Rs】	
		08:00-09:00	※ <b>值班主治醫師查房</b> ※ Answers of the last week's case: lichen planopilaris	
四	6/1			
五	6/2	08:00-09:00		
六	6/3			
日	6/4			