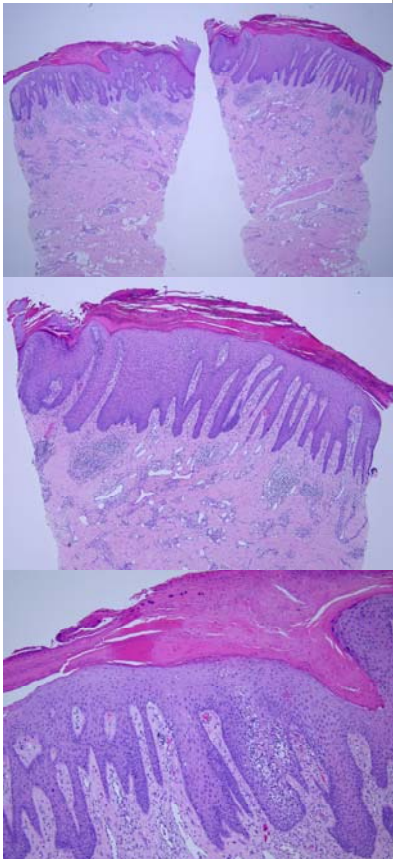


星期	日期	時間	活動	Case of the week
一	04/03			<p>This 74 years old male with no underlying disease. He present with a erythematous hyperkeratotic plaque over the right buttock, near gluteal fold for a period. The lesion showed slightly surface crusting and had an hyperkeratotic rim-like border.</p> 
二	04/04		清明連假	
三	04/05		清明連假	
四	04/06	08:00-08:30	<p>※皮外期刊討論會: Dermatologic Surgery (Jonathan Kantor) Chapter 12: Local Anesthesia, Regional Nerve Blocks, and Postoperative Pain Management R3黃信奮/VS何英右 (3F門診討論室)【全科人員】</p>	
		08:30-09:00	<p>※ 臨床病例討論會: 1. Resolution of verruca vulgaris treated with HPV vaccine 2. Review of dysplastic nevus syndrome and follow up (3F門診討論室)【全科人員】 R1曾怡倫 / VS朱家葆 R1曾怡倫 / VS李玉雲</p>	
五	04/07	08:00-09:00	<p>※ 住院醫師讀書會 Fitzpatrick 9e. Ch 178+180 R4 陳麒亘 (3F門診討論室)【Rs】</p>	
六	04/08			
日	04/09		<p>※ 值班主治醫師查房 ※ Answer for the last week's case: apocrine cystadenoma</p>	