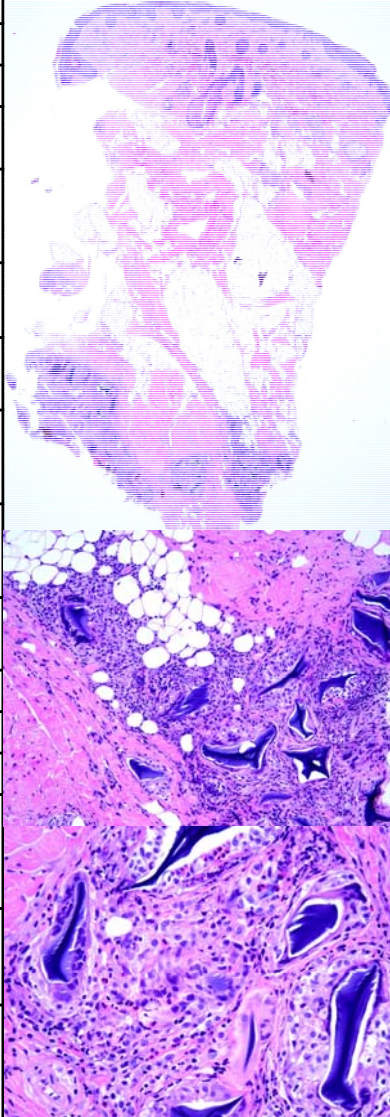


星期	日期	時間	活動	Case of the week
—	03/06	08:30-09:00	小科會 (3F門診討論室)【主任, Rs】	<p>This is a 52-year-old female with a few asymptomatic 0.5-3 cm irregular firm nodules without skin color change over chin for 1 week.</p> 
		12:00-13:00	※ 外賓演講: How to Give a Good Lecture Prof. John McGrath (醫學院第一講堂)【全科人員】	
二	03/07	08:00-08:30	※ 臨床病例討論會 1. A case of angioma serpiginosum 2. Review of pemetrexed induced pseudocellulitis	
		08:30-09:00	※ 出院病例討論會 R1 曾怡倫 (3F門診討論室)【全科人員】	
		08:00-09:00	※ 住診教學 VS 李兆甯 (11B討論室)【Clerks, PGYs, Rs】	
		13:00-15:00	※ 臨床病理討論會 (括弧內為討論重點) 1. Skin, back; shave biopsy: Poroma. ( <a href="#">The clinicopathological review of Poroma</a> ) 2. Skin, nasal bridge, right, biopsy: Basal cell carcinoma. ( <a href="#">The clinicopathological review of morphea type BCC</a> ) 3. Toe, 4th, left, excision: Fibrokeratoma with focal ulceration. ( <a href="#">The clinicopathological review of fibrokeratoma</a> ) 4. Soft tissue, face, left; biopsy: Granulomatous inflammation. ( <a href="#">The clinicopathological review of tuberculoid granulomatous dermatitis</a> ) 5. Skin, scalp, right; biopsy: Epidermal necrosis with a subepidermal vesicle. ( <a href="#">The clinicopathological review of coma blister</a> ) 6. Skin, thigh, right; biopsy: Consistent with phaeohyphomycosis. ( <a href="#">The clinicopathological review of exophiala and other phaeohyphomycosis dermatitis</a> )	
			VS 趙曉秋 VS 王德華 VS 何英右 VS 朱家葆 VS 何英右 VS 李玉雲	
		15:00-16:00	※ 廠商演講: 玻尿酸治療: 無菌操作說明介紹+demo 愛力根醫學美容 (3F門診討論室)【全科人員】	
		17:30-18:30	科會 (線上會議)【VS, CRs】	
四	03/09	08:00-09:00	※ 期刊討論會 Exosomes Derived from Epidermal Stem Cells Improve Diabetic Wound Healing (Journal of Investigative Dermatology (2022) 142, 2508-2517) R1 曾怡倫 / VS 楊朝鈞 (3F門診討論室)【全科人員】	
五	03/10	08:00-09:00	※ 住院醫師讀書會: Fitzpatrick 9e Ch. 177 R2 王瀚棠 (3F門診討論室)【Rs】	
六	03/11		※ 值班主治醫師查房	
日	03/12		※ Answer for the last week's case: cutaneous mucinous carcinoma	