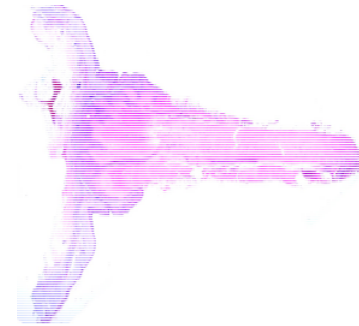
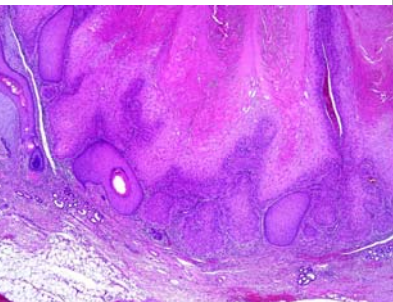
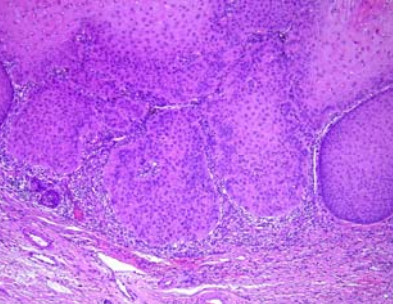


星期	日期	時間	活動	Case of the week
一	02/20	12:000-13:00	※ 廠商demo: 585nm 黃雷射 (沃醫學) (雷射美容中心)【全科人員】	.A 84 years old female with underlying disease of DM CKD, HCV and HTN. She regularly followed up at our OPD for many actinic keratosis on face. This time, she complaint of a narrowed- based keratotic spike on right cheek for a period.
二	02/21	08:00-09:00	※ Research seminar: 1. A 33-year-old female presenting with multiple itchy erythematous or slate-grey papules and plaques on the left shin 2. The role of Next-generation Sequencing in Skin Research R1 賴奕慈/VS許釗凱 (3F門診討論室)【全科人員】	
三	02/22	08:10-09:00 13:00-15:00	※ 住診教學 VS 何英右 (11B討論室)【Clerks, PGYs, Rs】 ※ 臨床病理討論會 (括弧內為討論重點) 1. Skin, dorsal foot, right, biopsy: Ulcer..(Clinicopathology of mycobaterium marinum infection) 2. Eyelid, lateral, right; biopsy: (Suggestive of primary cutaneous) mucinous carcinoma. (Clinicopathology of cutaneous mucinous carcinoma) 3. Skin, vertex scalp, biopsy: Peri-infundibular inflammatory inifltrate with foreign body giant cells.(Differential diagnosis of lichen planopilaris and central centrifugal cicatricial alopecia) 4. Skin, back, biopsy: Vacuolar interface dermatitis..(A case of suspected multi-vitamin supplement related drug eruption) 5. Soft tissue, chin, biopsy: Foreign body reaction. (Clinicopathology of hyalruonic acid injection (V18)) 6. Skin, thigh, right, biopsy: Subcorneal pustule with fungal infection (Revire of EGFRi cutaneous side effects) R2葉芮彤/ VS 李玉雲 (3F門診討論室&線上會議)【全科人員】	
四	02/23	08:00-09:00	※ NP衛教 冬季濕疹及冬季搔癢症 NP王愛怡/VS廖怡貞 (3F門診討論室)【全科人員】 ※ 外訓醫師報告 Pruritus in the Elderly 成大家醫科 R鄭姿綺/VS朱家葆 ※ PGY seminar Late-onset complications of dermal filler PGY許祐璋/VS楊朝鈞	  
五	02/24	08:00-09:00	※ 住院醫師讀書會 Fitzpatrick 9e. Ch 170 R4 曾怡倫 (3F門診討論室)【Rs】	
六	02/25		※ 值班主治醫師查房	
日	02/26			※ Answer for the last week's case: myoepithelial carcinoma