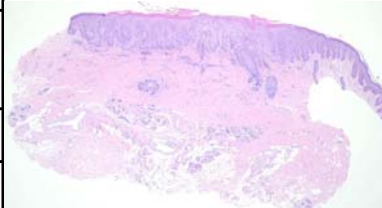
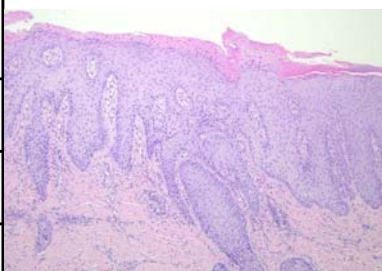
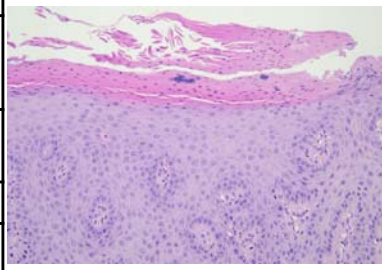
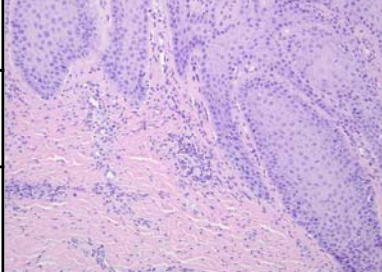


| 星期 | 日期    | 時間          | 活動   | Case of the week   |
|----|-------|-------------|--|--|
| 一  | 01/09 |             |  |  |
| 二  | 01/10 | 08:00-08:30 | ※ 臨床病例討論會<br>R1 賴奕慈 (3F門診討論室) 【全科人員】<br>1. Erythema multiforme minor developed after MMR vaccination<br>VS 李兆甯   | This is a 26-year-old female with some itchy blaschkoid hyperkeratotic papules on right inner thigh since birth.   |
|    |       |             | 2. Tinea Capitis in Infants<br>VS 許釗凱  |  |
|    |       | 08:30-09:00 | ※ 出院病例討論會<br>R1 曾怡倫 (3F門診討論室) 【全科人員】   |   |
| 三  | 01/11 | 08:00-09:00 | ※ 住診教學<br>VS 杜威廷 (11B討論室) 【Clerks, PGYs, Rs】   |  |
|    |       | 13:00-15:00 | ※ 臨床病理討論會 (括弧內為討論重點)<br>1. Skin, ear, left; excision: Keloid. ( <a href="#">The clinicopathological review of keloid</a> )<br>VS 杜威廷<br>2. Skin, face, right; excision: Suture granuloma with chronic active inflammation. ( <a href="#">The clinicopathological review of suture granuloma</a> )<br>VS 趙曉秋<br>3. Skin, lateral sole, right; biopsy: Orthokeratosis. ( <a href="#">The clinicopathological review of palmoplantar keratoderma and Olmsted syndrome</a> )<br>VS 許釗凱<br>4. Skin, thigh, right; biopsy: Neutrophilic dermatitis with subcutaneous tissue involvement and early vasculitis. ( <a href="#">The clinicopathological review of vasculitis in neutrophilic dermatosis</a> )<br>VS 楊省三<br>5. Skin, forearm, right, excision: Nodular fasciitis. ( <a href="#">The clinicopathological review of nodular fasciitis</a> )<br>VS 劉威廷<br>6. Skin, cheek, left, wide excision: Microcystic adnexal carcinoma. ( <a href="#">The clinicopathological review of microcystic adnexal carcinoma</a> )<br>ENT 張展旗<br>R2 王瀚棠 / VS 李玉雲 (3F門診討論室) 【全科人員】 | <br><br> |
| 四  | 01/12 | 08:00-09:00 | ※ 期刊討論會<br>1. Optimal diagnosis and management of common nail disorders (Ann Med. 2022 Dec;54(1):694-712.)<br>R1 曾怡倫 / VS 趙曉秋(3F門診討論室) 【全科人員】  |  |
| 五  | 01/13 | 08:00-09:00 | ※ 住院醫師讀書會: Fitzpatrick 9e Ch. 165<br>R2 王瀚棠 (3F門診討論室) 【Rs】   |  |
| 六  | 01/14 |             | ※ 值班主治醫師查房   |  |
| 日  | 01/15 |             | ※ Answer for the last week's case: folliculosebaceous cystic hamartoma   |  |