
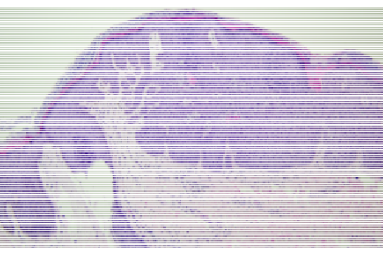
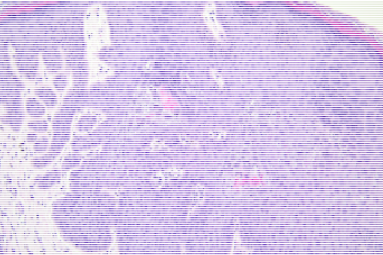
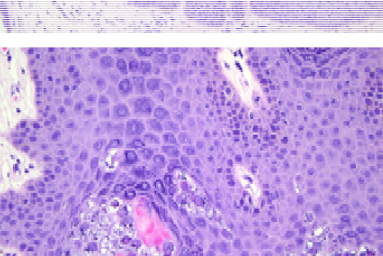



星期	日期	時間	活動	Case of the week
一	09/19			
二	09/20	08:00-08:20	※ 死亡病例討論會 R1 曾怡倫 (線上會議) 【全科人員】	This is a 66-year-old man with some pinhead-sized round to oval whitish verrucous papules around the anus for 6 months 
		08:20-08:40	※ 臨床病例討論會 1. Review of oculocutaneous albinism 2. Differential diagnosis of nevus flammeus and salmon patch R1 賴奕慈 (線上會議) 【全科人員】 VS 許釗凱 VS 趙曉秋	
		08:40-09:00	※ 出院病例討論會 R1 曾怡倫 (線上會議) 【全科人員】	
三	09/21	08:00-09:00	※ 住診教學 VS 王德華 (11B討論室) 【Clerks, PGYs, Rs】	  
		13:00-15:00	※ 臨床病理討論會 (括弧內為討論重點) 1. Skin, thigh, right; biopsy: Ulcer, compatible with ecthyma vulgaris with a reactive perforating collagenosis-like pattern. (The clinicopathological review of ecthyma vulgaris) 2. Skin, lower lip; biopsy: Capillary hemangioma. (The clinicopathological review of melanotic macules on lip) 3. Skin, left forearm, excision: Compatible with large B-cell lymphoma, recurrent. (The clinicopathological review of cutaneous presentation of diffuse large B cell lymphoma) 4. Skin, forearm, right; biopsy: superficial and deep mixed cell infiltration. (The clinicopathological review of lymphomatoid papulosis) 5. Skin, inner thigh, left; biopsy: Suggestive of bullous pemphigoid. (The clinicopathological review of bullous lupus erythematosus) 6. Skin, thigh, right; biopsy: Compatible with pemphigus. (The clinicopathological review of pemphigus) VS 劉威廷 VS 趙曉秋 VS 趙曉秋 VS 趙曉秋 VS 何英右 VS 朱家葆	
			R2 王瀚棠 / VS 李玉雲 (線上會議) 【全科人員】	
四	09/22	08:00-09:00	※ 研究討論會 (線上會議) 【全科人員】 1. Review of Therapeutic Response of Vitiligo in NCKUH Dermatology Department R2 王瀚棠 / VS 楊省三 2. An update on pathogenesis of vitiligo: anatomically distinct fibroblast subsets determine skin autoimmune patterns VS 楊省三	
		16:00-17:00	※ 皮膚整外討論會 (3樓門診會議室) 【全科人員】	
五	09/23	08:00-09:00	※ 住院醫師讀書會 : Fitzpatrick 9e Ch.147 R3 黃信奮 (3F門診會議室) 【Rs】	
六	09/24		※ 值班主治醫師查房 ※ Answer for the last week's case: Galli-Galli disease	
日	09/25			