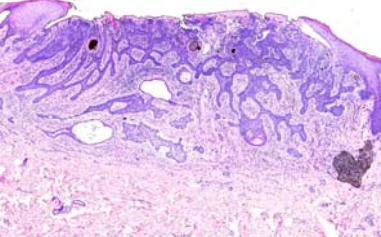
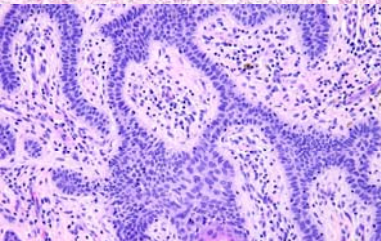
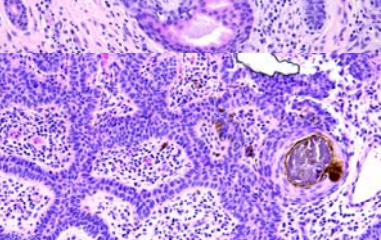
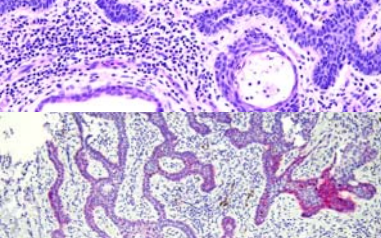


Weekly Schedule of NCKUH Dermatology Department (2022.08.29~2022.09.04)

製表: R4陳萱/ VS楊朝鈞

星期	日期	時間	活動	Case of the week	
一	08/29	12:00-13:00	※ 腫瘤團隊會議	<p>The 69 y/o female had no systemic illness, but multiple BCC history. She came for help over one 0.5cm pigmented papule with central ulceration at gluteal groove noted since</p>    	
二	08/30	08:00-09:00	※ 臨床病例討論會: R1曾怡倫(視訊會議)【全科人員】 1. Purpuric drug eruption caused by EGFR inhibitor VS 楊省三 2. Review of melanoma treatment with scout biopsy VS 何英右		
			※ 出院病例討論會 R1賴奕慈(視訊會議)【全科人員】		
三	08/31	08:10-09:00	※ 住診教學 VS 廖怡貞 (11B討論室)【Clerks, PGYs, Rs】		
		12:00-13:00	※ R1 orientation: 皮膚色素異常症 VS 楊省三		
		13:00-15:00	※ 臨床病理討論會 (括弧內為討論重點)		VS許釗凱
			1. Skin, calf, left; biopsy: Granulomatous dermatitis with subcutaneous tissue involvement, compatible with necrobiosis lipoidica diabetorum (Clinicopathology of necrobiosis lipoidica)		VS廖怡貞
			2. Skin, glabella; biopsy: Perivascular dermatitis with possible sebaceous hyperplasia.(Clinicopathology of rosacea)		VS吳昱學
			3. Skin, lower lip, left, biopsy: Candida infection.(Clinicopathology of candida-associated cheilitis)		VS楊省三
			4. Skin, ankle, right, biopsy: Mycosis fungoides, recurrent.(Clinicopatholgy of mycosis fungoides)		VS杜威廷
			5. Soft tissue, intergluteal fold; excision: Consistent with pilonidal cyst.. (A case of bullous pemphigoid with eosinophils line up at the dermoepidermal junction)	VS李兆甯	
	6. Soft tissue, left face; biopsy: Squamous cell carcinoma, well differentiated, with focal keratoacanthoma features. (Clinicopathology : Compare well-differentiated SCC and keratoacanthoma)				
		R2 葉芮廷 / VS 李玉雲 (視訊會議)【全科人員】			
四	09/01	08:00-09:00	※ 期刊討論會 1. Skin cancer: Primary, secondary, and tertiary prevention. Part II (J Am Acad Dermatol 2022 Aug; 87(2): 271-288) R3黃信奮 / VS何英右 2. Monkeypox Virus Infection in Human across 16 Countries — April–June 2022 (N Engl J Med. 2022 Aug 25;387(8):679-691) R4陳萱 / VS何英右 (視訊會議)【全科人員】		
五	09/02	08:00-09:00	※ 住院醫師讀書會: Fitzpatrick 9e Ch.143, 144 R2王瀚棠/ R2 葉芮廷(3F門診討論室)【Rs】		
六	09/03		※ 值班主治醫師查房	Ber-EP4	
日	09/04				
			※ Answer for the last week's case: alopecia areata		