本週值班 VS：
何英右醫師

Weekly Schedule of NCKUH Dermatology Department (2022.03.14~2022.03.20)

製表：R3陳麒亘 / VS楊朝鈞

星期	日期	時間	活動	
一	03/14			
二	03/15	08:00-08:30	※ 臨床病例討論會 R1 葉芮妲 (3F門診討論室)【全科人員】	
			1. Review of hair loss associated with isotretinoin	VS 楊朝鈞
			2. Review of neonatal erythroderma	VS 杜威廷
		08:30-09:00	※ 出院病例討論會 R1 王瀚棠 (3F門診討論室)【全科人員】	
三	03/16	08:00-09:00	※ 住診教學 VS 何英右 (11B討論室)【Clerks, PGYs, Rs】	
		13:00-15:00	※ 臨床病理討論會 **(括弧內為討論重點)**	
			1. Skin, arm, left; biopsy: Ulcer with suppurative granulomatous dermatitis. (Review of BCG-induced cutaneous reactions)	VS 李兆甯
			2. Skin, cheek, right; biopsy: Perifollicular suppurative and granulomatous dermatitis. (Review of granulomatous rosacea and lupus miliaris disseminatus faciei)	VS 杜威廷
			3. Skin, ear auricle, left, biopsy: Malignant melanoma. (Review of atypical Spitzoid tumor and Spitzoid melanoma)	VS 楊朝鈞
			4. Skin, upper abdomen; biopsy: Spongiotic psoriasiform dermatitis. (Review of Gianotti-Crosti syndrome)	VS 何英右
			5. Skin, cheek, right; biopsy: Suggestive of acanthosis nigricans. (Review of acanthosis nigricans & confluent and reticular papillomatosis)	VS 楊省三
			6. Skin, cheek, right; biopsy: Superficial perivascular dermatitis with dermatophyte infection. (Review of incidental acantholysis and possible association between superficial fungal infection and pemphigus vulgaris)	VS 許釗凱
			R2 黃信畬 / VS 李玉雲 (3F門診討論室)【全科人員】	
四	03/17	08:00-08:10	※專師衛教：異位性皮膚炎 NP 王愛怡 / VS 廖怡貞 (3F門診討論室)【全科人員】	
		08:10-08:40	※期刊討論會 Combination of 5-Aminolevulinic acid photodynamic therapy and isotretinoin to treat moderate-to-severe acne (Photodiagnosis Photodyn Ther. 2021 Jun;34:102215.) R3 陳萱 / VS 王德華 (3F門診討論室)【全科人員】	
五	03/18	08:00-09:00	※ 住院醫師讀書會: Fitzpatrick 9e Ch. 111-112 R2 黃信畬 /R2 林謙 (3F門診討論室)【Rs】	
六	03/19		※ 值班主治醫師查房	
日	03/20			

※ Answer for the last week's case: Kyrle's Disease

Case of the week
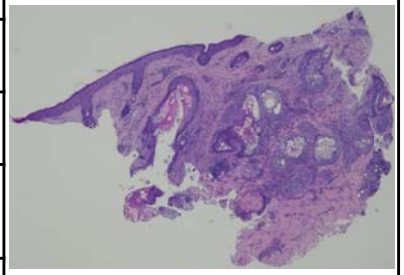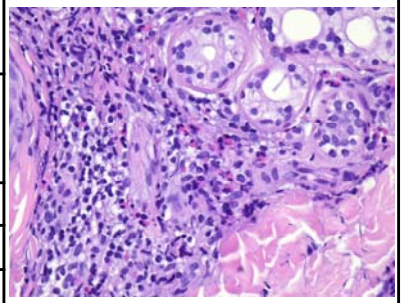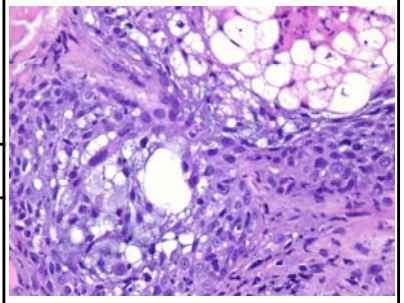
This is a 24-year-old woman with several pea-sized irregular erythematous papules for 1.5 years