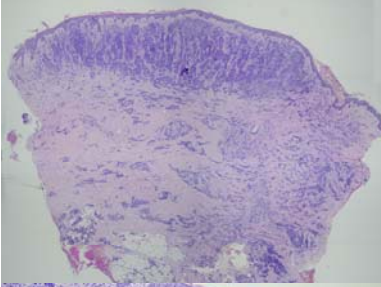
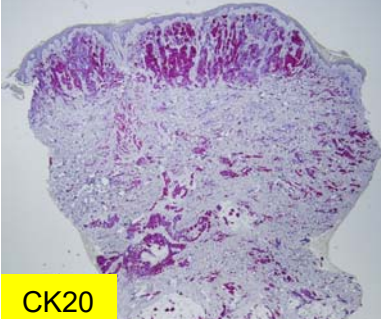


星期	日期	時間	活動	Case of the week
一	10/17			
二	10/18	08:00-09:00	※ 臨床病例討論會: 1. Update of pathophysiology and management of pruritus in elderly (視訊會議)【全科人員】 R2 葉芮廷 VS 楊省三 R2 王瀚棠 VS 許釗凱 2. Itch evaluation in EB ※ 出院病例討論會 R1賴奕慈 (視訊會議)【全科人員】	This is a 72 years old male with underlying disease of EMPD, perianal area, s/p excision, photodynamic therapy and chemotherapy. This time, he was admitted due to E. coli bacteremia. During hospitalization, there were several round to ovoid erythematous papules over inguinal are with red patches at background.
三	10/19	08:10-09:00	※ 住診教學 VS 楊省三 (11B討論室)【Clerks, PGYs, Rs】	
		13:00-15:00	※ 臨床病理討論會 (括弧內為討論重點) 1. Skin, thigh, right, excision: Hidradenoma.(Clinicopathology of cutaneous non-tuberculosis infection) VS趙曉秋 2. Skin, thigh, right, biopsy: Suppurative granulomatous inflammation.(Clinicopathology of adult xanthogranuloma) VS杜威廷 3. Skin, flank, right, biopsy: Hyperpigmentation, mild.(Differential diagnosis of ashy dermatoses, idiopathic eruptive macular hyperpigmentation and post-inflammatory hyperpigmentation) VS王德華 4. Lip, lower; biopsy: Suggestive of plasma cell cheilitis/mucositis.(Clinicopathology of plasma cell cheilitis/mucositis) VS杜威廷 5. Skin, buttock, left; biopsy: Compatible with pityriasis lichenoides et varioliformis acuta. (Clinicopathology of PLEVA) VS王德華 6. Skin, cheek, left, biopsy: Foreign body granuloma. (A case of foreign body granuloma on face, suspect siliconoma-related. ) VS朱家葆 R2 葉芮廷 / VS 李玉雲 (視訊會議)【全科人員】	
四	10/20	08:00-08:20	※ PGY seminar The clinical value of 18F-FDG PET imaging for staging in melanoma patients PGY張藝瀚/VS劉威廷 (視訊會議)【全科人員】	
		08:20-09:00	※ 第48屆年會預報 1. A young girl presenting with an enlarging annular tumid lupus erythematosus with additional histologic features of lymphocytic thrombophilic arteritis (R2葉芮廷/VS李玉雲) 2. A case of pembrolizumab-induced acute generalized exanthematous pustulosis and subsequent toxic epidermal necrolysis successfully treated by etanercept (R2王瀚棠/VS許釗凱) 3. Herpes Zoster Ophthalmicus with Delayed Onset of Facial Palsy and Aseptic Meningitis: a Case Report and Literature Review (R1賴奕慈/VS廖怡貞) 4. To Switch or Not to Switch? The Choice of Biologic Agents upon Relapse of Chronic Plaque Psoriasis Following Treatment Discontinuation (R3黃信奮/VS李兆甯) (視訊會議)【全科人員】	
五	10/21	08:00-09:00	※ 住院醫師讀書會 Fitzpatrick 9e. Ch.151+157 R1賴奕慈 (3F門診討論室)【Rs】	
六	10/22		※ 值班主治醫師查房	
日	10/23		※ Answer for the last week's case: Exostosis	CK20