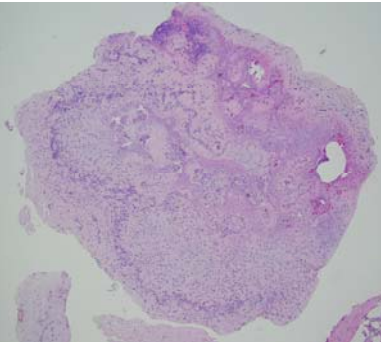
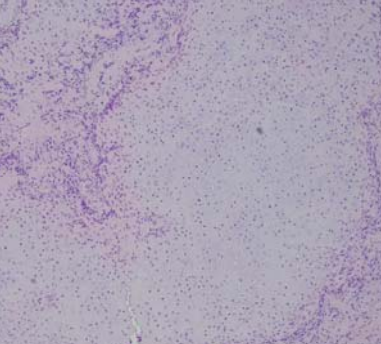
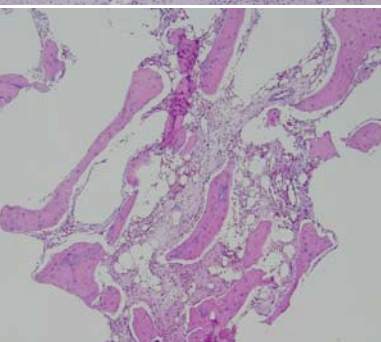


星期	日期	時間	活動	Case of the week
一	10/10		雙十節連假	A 10 years old boy with no underlying disease. He present to our department for a subungual protruding mass over right big toe for a long period. The overlying nail showed demornity.
二	10/11	08:00-09:00	※ 臨床病例討論會: 1. Review of vitiligo scoring for evaluation and follow-up 2. Review of drug induced lupus erythematosus R2 王瀚棠 (視訊會議) 【全科人員】 VS 楊省三 VS 許釗凱 ※ 出院病例討論會 R1曾怡倫 (視訊會議) 【全科人員】	
三	10/12	08:10-09:00	※ 住診教學 VS 楊省三 (11B討論室) 【Clerks, PGYs, Rs】	
		13:00-15:00	※ 臨床病理討論會 (括弧內為討論重點) 1. Skin, thigh, right, excision: Hidradenoma.(Clinicopathology of cutaneous non-tuberculosis infection) 2. Skin, thigh, right, biopsy: Suppurative granulomatous inflammation.(Clinicopathology of adult xanthogranuloma) 3. Skin, flank, right, biopsy: Hyperpigmentation, mild.(Differential diagnosis of ashy dermatoses, idiopathic eruptive macular hyperpigmentation and post-inflammatory hyperpigmentation) 4. Lip, lower; biopsy: Suggestive of plasma cell cheilitis/mucositis.(Clinicopathology of plasma cell cheilitis/mucositis) 5. Skin, buttock, left; biopsy: Compatible with pityriasis lichenoides et varioliformis acuta. (Clinicopathology of PLEVA) 6. Skin, cheek, left, biopsy: Foreign body granuloma. (A case of foreign body granuloma on face, suspect siliconoma-related.) VS趙曉秋 VS杜威廷 VS王德華 VS杜威廷 VS王德華 VS朱家葆 R2 葉芮彤 / VS 李玉雲 (視訊會議) 【全科人員】	 
		17:30-18:30	※ 科會 (視訊會議) 【主治醫師,CRs】	
四	10/13	08:00-08:20	※ 期刊討論會 Melanoma: An update on systemic therapies (J Am Acad Dermatol. 2022 Mar;86(3):515-524.) R4陳麒亘/VS劉威廷 (視訊會議) 【全科人員】	
		08:20-09:00	※ 第48屆年會預報 1. Novel compound heterozygous NTRK1 mutations in a Taiwanese male with congenital insensitivity to pain with anhidrosis (CIPA): a case report and literature review PGY張藝瀚/VS許釗凱 2. The clinicopathological study of genitogluteal porokeratosis: a rare disease entity with overlooked disease burden and unsatisfactory therapeutic response R1曾怡倫/VS杜威廷, 許釗凱, 李玉雲 3. Sporotrichosis revisited— 43 cases in Southern Taiwan from 1990 to 2005 and the identification of Sporothrix globosa as the pathogen R3林謙/VS楊朝鈞, 許明隆, 李玉雲 4. To Switch or Not to Switch? The Choice of Biologic Agents upon Relapse of Chronic Plaque Psoriasis Following Treatment Discontinuation R3黃信喬/VS李兆甯 (視訊會議) 【全科人員】	
五	10/14	08:00-09:00	※ 住院醫師讀書會 Fitzpatrick 9e. Ch.150 R1曾怡倫(3F門診討論室) 【Rs】	
六	10/15		※ 值班主治醫師查房	
日	10/16		※ Answer for the last week's case: livedoid vasculopathy	