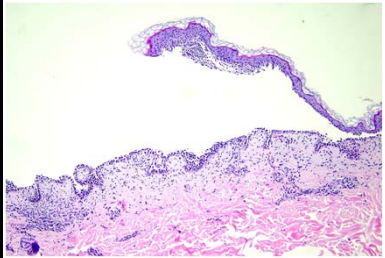
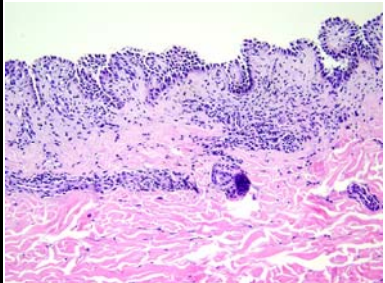
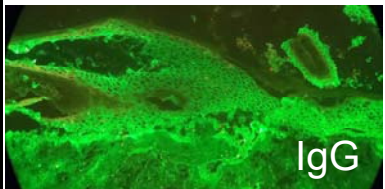


日期	時間	活動	Case of the week
6/26 週一			
6/27 週二	08:00-08:30	※ 臨床病例討論會 R2 葉芮苙 (3F門診討論室) 【全科人員】 1. A case of cutaneous Mycobacterium haemophilum infection with osteomyelitis /VS 李兆甯 2. Clinicopathology of chronic granulomatous disease /VS 許釗凱	A 49-year-old male with oral ulcer since 2022/11 and scattered flaccid blistered and crusted erosions at trunk and upper limbs for 1 month.
	08:30-09:00	※ 醫學倫理討論會 PGY 蔡裕曜 / VS 廖怡貞 (3F門診討論室) 【全科人員】	
6/28 週三	08:00-09:00	※ 住診教學 /VS 趙曉秋 (11B討論室) 【Clerks, PGYs, Rs】	  
	13:00-15:00	※ 臨床病理討論會 (括弧內為討論重點) R1 曾怡倫 / VS 李玉雲 (3F門診討論室) 【全科人員】 1. Skin, leg, right; biopsy: Perivascular lymphocytic infiltration with increased CD30-positive cells (The clinicopathological review of arthropod reaction with CD30 positive infiltrate and ulceration mimicking CD30 lymphoproliferative disorder .) /VS 趙曉秋	
		2. Skin, postauricular, left, biopsy: Angiosarcoma. (The clinicopathological review of angiosarcoma.) /VS 杜威廷	
		3. Soft tissue, lateral foot, left, excision: Angioleiomyoma. (The clinicopathological review of different types leiomyoma and hereditary leiomyomatosis and renal cell cancer.) /R4 陳麒亘	
		4. Skin, scalp, occipital, biopsy: Perifollicular granulomatous inflammation, compatible with scarring alopecia or acne keloidalis. (The clinicopathological review of acne keloidalis.) /VS 楊朝鈞	
		5. Skin, neck, right, excision: Pilomatrixoma. (The clinicopathological review of pilomatrixoma) /VS 杜威廷	
6. Skin, left labia majora, biopsy: Extramammary Paget's disease. (The clinicopathological review of extramammary Paget's disease and intraepithelial pagetoid neoplasms) /VS 趙曉秋			
6/29 週四	08:00-09:00	※ 全院CPC (醫學院2F第四講堂) 【全科人員】 A 10-year-old child with acute encephalitis.	
6/30 週五	08:00-09:00	※ 住院醫師讀書會: Fitzpatrick 9e Ch. 199 R2 葉芮苙 (3F門診討論室) 【Rs】	Answer for last week:
7/1 週六		※ 值班主治醫師查房	Epidermolysis bullosa pruriginosa
7/2 週日			