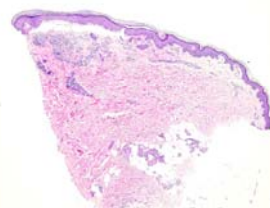
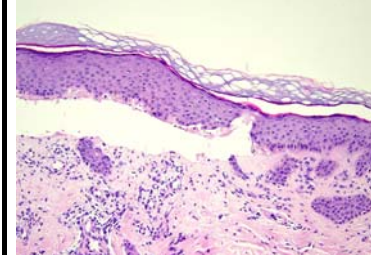



日期	時間	活動	Case of the week
6/19 週一			<p>A 32-year-old female with scattered tense blisters on the lower legs for 5 years with toenail dystrophies. Genetic study revealed heterozygous mutation in collagen 7.</p>   <p>EM: abnormal anchoring fibrils</p> 
6/20 週二	08:00-08:30	※ 研究討論會 /VS 何英右 & VS 李兆甯 (3F門診討論室) 【全科人員】 Psoriasis in the geriatric population: A retrospective study in Asians R1 曾怡倫	
	08:30-09:00	※ 出院病例討論會 R1 賴奕慈 (3F門診討論室) 【全科人員】	
6/21 週三	08:00-09:00	※ 住診教學 /VS 趙曉秋 (11B討論室) 【Clerks, PGYs, Rs】	
	13:00-15:00	※ 臨床病理討論會 (括弧內為討論重點) R1 曾怡倫 / VS 李玉雲 (3F門診討論室) 【全科人員】 1. Skin, lateral chest wall, right; biopsy: Suprabasal vesicular dermatitis with acantholysis, compatible with pemphigus (The clinicopathological review of pemphigus vulgaris and the meaning of C3 and C3 positive rate in PV cases.) /R3 林謙	
		2. Skin, nasal bridge, right, biopsy: Cutaneous anaplastic large cell lymphoma. (The clinicopathological review of cutaneous anaplastic large cell lymphoma.) /VS 趙曉秋	
		3. Skin, eyebrow, left; biopsy: Vacuolar interface dermatitis with thickened basement membrane zone, consistent with lupus erythematosus. (The clinicopathological review of lupus erythematosus and clinical review of unilateral type SLE.) /VS 李兆甯	
		4. Skin, foot, left, biopsy: Compatible with neutrophilic dermatosis. (The clinicopathological review of neutrophilic panniculitis and sweet-like panniculitis.) /VS 廖怡貞	
5. Skin, shin, left; biopsy: Orthokeratosis and epidermal hyperplasia. (The clinicopathological review of linear psoriasis.) /VS 李玉雲			
6. Skin, chest, biopsy: Adenocarcinoma, metastatic (The clinicopathological review of adenocarcinoma with skin metastasis.) /VS 廖怡貞			
15:00-16:00	※ 廠商演講 奇美醫院 鄭百珊醫師 (3F門診討論室) 【全科人員】 Updates on novel topical therapy for atopic dermatitis		
6/22 週四		※ 端午節國定假日	
6/23 週五	08:00-09:00	※ 住院醫師讀書會: Fitzpatrick 9e Ch. 195 R4 陳萱 (3F門診討論室) 【Rs】	
6/24 週六		※ 值班主治醫師查房	
6/25 週日			

Answer for last week:
Sarcomatoid carcinoma