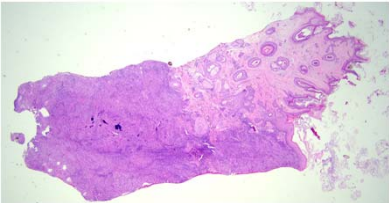
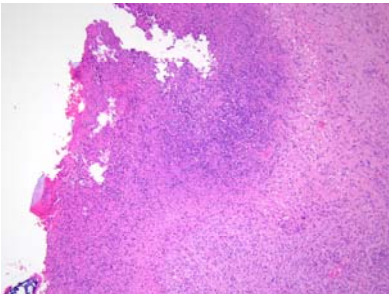
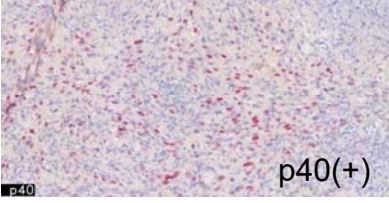


日期	時間	活動	Case of the week
6/12 週一	08:30-09:00	※ 小科會 (3F門診討論室) 【Rs, VS 楊朝鈞】	A 50-year-old male with a large and irregular firm tumor over central poor-healing wound over scalp for 3 years.
6/13 週二	08:00-08:30	※ 臨床病例討論會 1. A case of pediatric Ofuji's disease 2. Hair loss and lupus erythematosus R2 葉芮苙 (3F門診討論室) 【全科人員】 /VS 許釗凱 /VS 朱家葆	
	08:30-09:00	※ 出院病例討論會 R1 賴奕慈 (3F門診討論室) 【全科人員】	
6/14 週三	08:00-09:00	※ 住診教學 /VS 趙曉秋 (11B討論室) 【Clerks, PGYs, Rs】	   
	13:00-15:00	※ 臨床病理討論會 (括弧內為討論重點) R1 曾怡倫 / VS 李玉雲 (3F門診討論室) 【全科人員】	
		1. Skin, foot, right, excision: kaposi sarcoma (The clinicopathological review of kaposi sarcoma.) /VS 何英右	
		2. Skin, forearm, left; biopsy: Granuloma annulare (The clinicopathological review of Granuloma annulare.) /VS 朱家葆	
		3. Skin, frontal scalp, biopsy: Compatible with lichen planopilaris (The clinicopathological review of lichen planopilaris) /VS 楊朝鈞	
		4. Skin, lower leg, right; biopsy: Epidermolysis bullosa pruriginosa (The clinicopathological review of epidermolysis bullosa pruriginosa.) /VS 許釗凱	
5. Skin, thigh, left; biopsy: Consistent with erythema elevatum diutinum-like chronic leukocytoclastic vasculitis (The clinicopathological review of erythema elevatum diutinum.) /VS 朱家葆			
6. Skin, lower eyelid, right, biopsy: In favor of basal cell carcinoma. (The clinicopathological review of infiltrative basal cell carcinoma) /VS 趙曉秋			
15:00-17:00	※ 廠商演講 Allergen Medical Institute (3F門診討論室) 【Rs, VS】 Top Gun Aesthetic Program - Lower Face		
17:30-18:30	※ 科會 (視訊會議) 【總醫師及主治醫師】		
6/15 週四	08:00-08:30	※ 期刊討論會 /VS 杜威廷 (3F門診討論室) 【全科人員】 Consensus guidelines for diagnosis and management of anemia in epidermolysis bullosa. Orphanet J Rare Dis. 2023 Feb 23;18(1):38. R4 陳萱	
6/16 週五	08:00-09:00	※ 住院醫師讀書會: Fitzpatrick 9e Ch. 194 R4 陳麒巨 (3F門診討論室) 【Rs】	
6/17 週六		※ 值班主治醫師查房	
6/18 週日			▼ Answer for last week's case
	09:50-12:00	※ 112年度第2次雲嘉南區聯合病例討論會 (視訊會議)	Juvenile xanthogranuloma