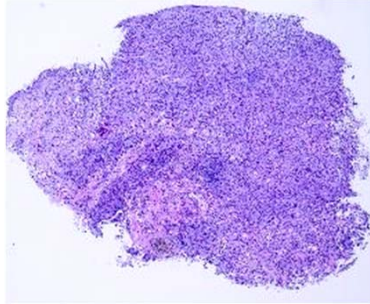
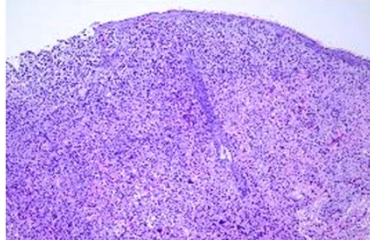
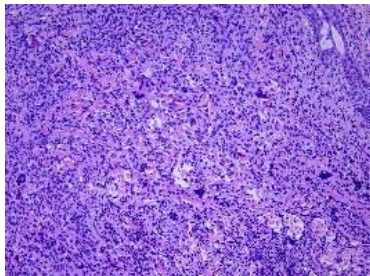
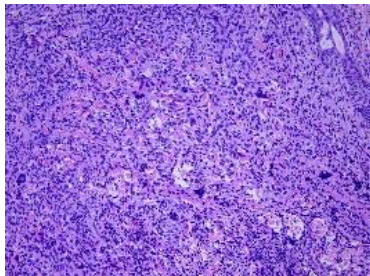


日期	時間	活動	Case of the week	
6/5 週一			A 1 y/o girl, with a 0.5-cm asymptomatic yellowish papule over left preauricle area for 3 months.	
6/6 週二	08:00-08:30	※ 研究討論會 Inherited palmoplantar keratodermas VS 杜威廷 (3F門診討論室) 【全科人員】		
	08:30-09:00	※ 出院病例討論會 R1 賴奕慈 (3F門診討論室) 【全科人員】		
6/7 週三	08:00-09:00	※ 住診教學 /VS 趙曉秋 (11B討論室) 【Clerks, PGYs, Rs】	  	
	13:00-15:00	※ 臨床病理討論會 (括弧內為討論重點)		R2 王瀚棠 / VS 李玉雲 (3F門診討論室) 【全科人員】
		1. Skin, leg, left; biopsy: Consistent with allergic reactions. (The clinicopathological review of eosinophilic cellulitis.)		/VS 何英右
		2. Skin, cheek, left, biopsy: Angioinvasive fungal infection (see description). (The clinicopathological review of angioinvasive aspergillosis)		/VS 廖怡貞
		3. Skin, left cheek, biopsy: Spongiotic and vacuolar interface dermatitis. (The clinicopathological review of facial discoid dermatosis)		/VS 廖怡貞
		4. Skin, scalp, left, biopsy: Xanthogranuloma. (The clinicopathological review of juvenile xanthogranuloma vs reticulohistiocytoma)		/VS 何英右
5. Skin, forehead; biopsy: Compatible with linear scleroderma (en coup de sabre). (The clinicopathological review of en coup de sabre and Lichen sclerosus et atrophicus)	/VS 趙曉秋			
6. Nose, columella, biopsy: Inflamed granulation tissue. (The clinicopathological review of Complication of rhinoplasty (use ear cartilage))	/R3 林謙			
6/8 週四	08:00-08:30	※ 期刊討論會 Sprecher E. et al. Defective cathepsin Z affects EGFR expression and causes autosomal dominant palmoplantar keratoderma. Br J Dermatol. 2023 May 20;ljad167. /VS 杜威廷 (3F門診討論室) 【全科人員】		
	08:30-09:00	※ 職業性皮膚病與職災通報 職業醫學科 (3F門診討論室) 【全科人員】 R1 曾怡倫		
6/9 週五	08:00-09:00	※ 住院醫師讀書會: Fitzpatrick 9e Ch. 193 R3 林謙 (3F門診討論室) 【Rs】		
6/10 週六		※ 值班主治醫師查房	▼ Answer for last week's case Merkel cell carcinoma	
6/11 週日				