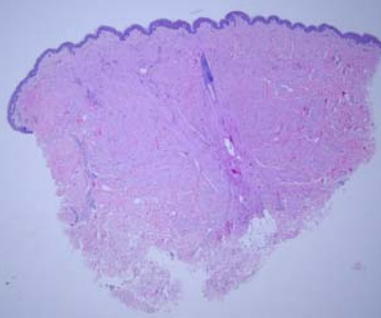
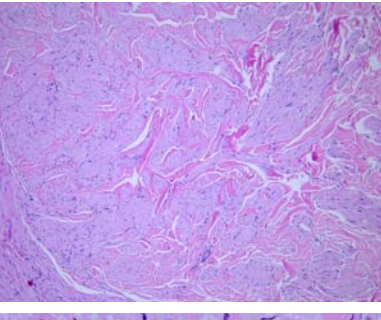


星期	日期	時間	活動	Case of the week
一	04/10	08:30-09:00	※小科會 (住院醫師辦公室)【Rs】	A 66 years old female without underlying disease. She present to our OPD for two elastic nodule over her lower back for a period. The size of the lesions are 0.3 and 0.5 cm in diameter respectively.
二	04/11	08:00-08:30	※期刊討論會: Pustular psoriasis: Molecular pathways and effects of spesolimab in generalized pustular psoriasis (J Allergy Clin Immunol. 2022 Apr;149(4):1402-1412.) R3林謙/VS許釗凱 (3F門診討論室)【全科人員】	
		08:30-09:00	※出院病理討論 R1賴奕慈(3F門診討論室)【全科人員】	
三	04/12	08:10-09:00	※住院醫師讀書會 Fitzpatrick 9e. Ch 182 R4 陳萱 (3F門診討論室)【Rs】	
		13:00-15:00	※臨床病理討論會 (括弧內為討論重點) 1. Skin, perineum, right; biopsy: Molluscum contagiosum.(Clinicopathology and treatment of molluscum contagiosum) VS趙曉秋 2. Skin, ear, left, excision: Keloid..(Differential diagnosis of keloid and sclerotic fibroma) VS何英右 3. Skin, lower lip, biopsy: Compatible with lichen planus..(Clinicopathology of lichen planus) VS朱家葆 4. Skin, thigh, left; biopsy: Vacuolar interface dermatitis with necrotic keratinocytes, consistent with severe drug eruption..(The clinicopathological review of Drug reaction with eosinophilia and systemic symptoms (DRESS)) VS杜威廷 5. Skin, arm, right, biopsy: Compatible with VZV infection with interface dermatitis. (The clinicopathological review of VZV infection and herpetic cytopathic change.) VS許釗凱 6. Skin, upper lid, left, biopsy: Xanthelasma. (The clinicopathological review of xanthelasma) VS廖怡貞 R2葉芮彤/ VS 李玉雲 (3F門診討論室&線上會議)【全科人員】	
		17:30-18:30	※科會 (線上會議)【VS及CR】	
四	04/13	08:00-09:00	※臨床病例討論會: 1. Review of dysplastic nevus syndrome and follow up 2. Overview the sinonasal ecthyma gangrenosum and differential diagnosis with invasive fungal infection 3F門診討論室)【全科人員】 R1曾怡倫 / VS李玉雲 R1曾怡倫 / VS李兆甯	
五	04/14	08:00-09:00	※住診教學 VS 楊朝鈞 (11B討論室)【Clerks, PGYs, Rs】	
六	04/15		※值班主治醫師查房 ※ Answer for the last week's case: porokeratosis ptychotropica	
日	04/16			